

Topic: Tissue augmentation and engineering

Abstract

A 69-year woman presented for implant placement to support a full prosthesis with the least invasive shortest treatment; she requested no period without denture during the treatment. Posterior to the maxillary bicuspids, the residual bone height was between 2 and 5 mm. Sinus grafting was performed with only PRF through a crestal approach and implant placement was delayed. After a 12-weeks healing, six implants were placed; they were restored four months later. All implants achieved primary stability although bone density was poor. They were successfully loaded. After one year, they were clinically stable with a functional load. In the sinuses, newly formed mineralized tissue was visible but regenerated bone volumes were limited.

Background and Aim

Sinus grafting with delayed implant placement is indicated when the maxilla is severely atrophied and/or when no period without denture is requested. Many grafting materials are used to gain bone volume for implant placement. Autogenous bone grafting has been widely used despite increased morbidity. Bone substitutes avoid problems related to bone harvesting at secondary surgical sites but are reported to undergo a slow regeneration process. Until now, platelet-rich fibrin (PRF) has been proposed as substitution grafting material with simultaneous implantation (Diss et al. 2008, Mazor et al. 2009).

A patient asked for maxillary implant placement to support a full prosthesis with the least invasive shortest treatment; he requested no period without denture during the treatment. Osteotome sinus floor elevation was performed with only PRF through a crestal approach and implant placement was delayed. The one-year clinical performance of implants was assessed.

Methods and Materials

The patient: women, 69 years. Maxillary full rehabilitation.

Maxillary residual bone height: 2-5 mm

Implants: - Bone Level® (Ø4.1mm, length 10mm)

sites #13, #14, #23 and #24

- TE® (Ø4.8-6.5 mm, length 10 mm)

sites #16 and #26 (Straumann AG, Switzerland)

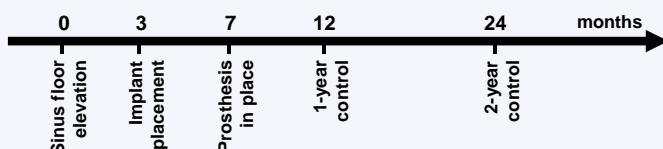
PRF preparation: from patient's centrifuged blood (Choukroun et al. 2001)

Sinus floor elevation: Through crestal sinus floor elevation, osteotomy sites were enlarged and the membrane integrity was controlled. PRF pieces were introduced, and flaps sutured.

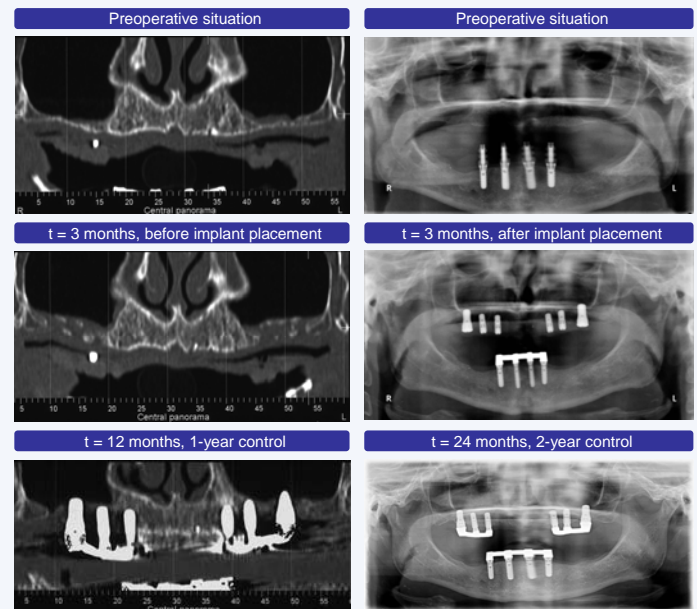
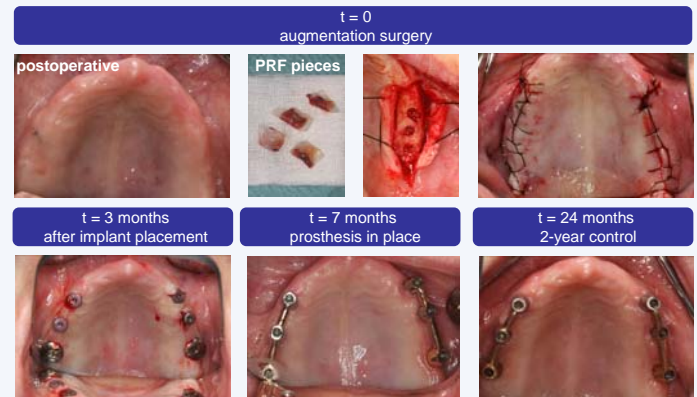
Implant placement: Three months later, implants were placed without tapping in a submerged manner.

Restoration: The 4-month healing period was uneventful. After exposure, implants were restored with an overdenture relying on six implants connected with two bars.

Follow-up: Panoramic x-ray and volumetric computed tomography to evaluate residual bone height and bone gain.



Results



All implants achieved primary stability although bone density was poor. They were successfully loaded.

After one year, they were clinically stable with a functional load. In the sinuses, newly formed mineralized tissue was visible but regenerated bone volumes were limited. Implants #26 and #16 showed a residual protrusion into the sinus of 2 and 4mm respectively.

Conclusions

This case report has shown that sinus grafting via a crestal approach can be managed within duration of three months using PRF. The introduction of PRF has contributed to maintain space for bone regeneration; however, bone density was poor and peri-implant bone formation was low.

References

- Choukroun J, Adda F, Schoeffler C, Vervelle A. (2001) An opportunity in perio-implantology: the PRF (in french). *Implantodontie* 42:55-62.
- Diss A, Dohan D, Mouhyi J, Mahler P. (2008) Osteotome sinus floor elevation using Choukroun's platelet-rich fibrin as grafting material: a 1-year prospective pilot study with microthreaded implants. *Oral Surg Oral Med Oral Pathol Oral Radiol Endod* 105:572-9.
- Mazor Z, Horowitz RA, Del Corso M, Prasad HS, Rohrer MD, Dohan Ehrenfest DM. (2009) Sinus floor augmentation with simultaneous implant placement using Choukroun's platelet-rich fibrin as the sole grafting material: a radiologic and histologic study at 6 months. *J Periodontol*. 80(12):2056-64.