

## **Short Implants Placed With or Without Grafting in Atrophic Sinuses: the 3-year Results of a Prospective Randomized Controlled Study**

Rabah Nedir DMD<sup>1</sup>, Nathalie Nurdin PhD<sup>2</sup>, Paul Khoury DDS, MS<sup>3</sup>, Mark Bischof DMD<sup>4</sup>

<sup>1</sup> Clinical Director, Swiss Dental Clinics Group, Ardentis Clinique Dentaire, Vevey, Switzerland.

<sup>2</sup> Senior Scientist, Swiss Dental Clinics Group, Ardentis Clinique Dentaire, Vevey, Switzerland.

<sup>3</sup> Dentist Collaborator, Swiss Dental Clinics Group, Ardentis Clinique Dentaire, Vevey, Switzerland; MD Assistant, Department of Stomatology and Oral Surgery, School of Dental Medicine, University of Geneva, Geneva, Switzerland.

<sup>4</sup> Clinical Director, Swiss Dental Clinics Group, Ardentis Clinique Dentaire, Lausanne, Switzerland.

### **Corresponding author**

Dr Rabah Nedir, Ardentis Clinique Dentaire Vevey, Rue du Collège 3, 1800 Vevey, Switzerland; phone: +41 58 234 00 10; e-mail: rabah.nedir@ardentis.ch.

### **Conflict of interest**

The authors declare that they have no conflict of interests.

### **Author contributions**

**Rabah Nedir:** Study concept and design, patient enrolment and surgery, data interpretation, critical revision of the article, submission approval, article approval.

**Nathalie Nurdin:** Study design, data analysis and interpretation, statistical analysis, article drafting and submission, article approval.

**Paul Khoury:** Data interpretation, critical revision of the article, submission approval, article approval.

**Mark Bischof:** Study concept, article revision, submission approval, article approval.

## **ABSTRACT**

*Background:* The question whether a minimal maxillary residual bone height (RBH) allows the predictable use of osteotome sinus floor elevation (OSFE) remains unresolved.

*Purpose:* To evaluate the efficacy of short implants placed with OSFE in an RBH of  $\leq 4$  mm and to compare bone levels around implants placed with (control) or without (test) grafting after 3 years.

*Materials and Methods:* Eight-millimetre implants were placed by OSFE in sinuses randomized to receive anorganic bovine bone or no grafting material. Healing time before prosthetic rehabilitation was 10 weeks. Peri-implant bone levels were measured on standardized peri-apical radiographs.

*Results:* Thirty-seven implants (17 test, 20 control) were placed at a mean RBH of  $2.4 \pm 0.9$  mm. Three implants failed during the 3-year follow-up. After 3 years, all implants had gained endo-sinus bone (test:  $4.1 \pm 1.0$  mm; control:  $5.1 \pm 1.2$  mm;  $p = 0.001$ ). Mean bone gain was stable between 1 and 3 years in both groups.

*Conclusions:* Grafting is unnecessary to achieve bone augmentation of 4.1 mm; however, more bone is gained with grafting. Bone gained over 1 year was retained. Atrophic posterior maxillae can be predictably rehabilitated using OSFE and simultaneous placement of 8-mm implants.

**Keywords:** bone grafting; bone regeneration; crestal approach; no grafting; osteotome sinus floor elevation; posterior maxilla; sinus lift.

## INTRODUCTION

Sinus floor augmentation and implant placement allow the rehabilitation of edentulous atrophic posterior maxillae. The lateral approach through a bony window, or the sinus-lift technique, is the conventional procedure for maxillary sinus floor augmentation. It permits access and elevation of the Schneiderian membrane: the cavity created beneath is then filled with autogenous bone or a bone substitute. In most cases, implant placement is delayed until subsequent surgery. Using implants with a rough surface, the 3-year implant survival rate can reach 96.5%.<sup>1</sup> However, this technique is considered invasive and time-consuming.

An alternative to the lateral approach is osteotome sinus floor elevation (OSFE) via a crestal approach. This technique involves drilling or trephining through the residual crestal bone up to the last millimetre. Membrane elevation is achieved using an osteotome by placing bone grafting material with apical condensation. The implant is generally placed simultaneously. The procedure is less invasive, treatment duration is reduced and postoperative discomfort is minimal. The primary stability of the implant and bone-implant contact is improved. The survival rate of implants placed using OSFE can reach 96.7% after 3 years,<sup>3</sup> which is comparable to that of the sinus-lift technique and to implants placed in non-augmented sites.<sup>4</sup>

The necessity of placing grafting material under the elevated sinus membrane is increasingly being questioned. A certain amount of intra-sinus bone volume can be regenerated around implants placed without any grafting material. This is obtained using sinus-lift<sup>5-8</sup> or OSFE.<sup>4,5,9-16</sup> By elevating the Schneiderian membrane, a compartment is created, which fills with a blood clot. The clot is thus protected and serves as a matrix for bone regeneration. Histological examinations in primates have

shown newly formed trabecular bone in close apposition to implants and lining the Schneiderian membrane.<sup>17</sup>

Although OSFE is a minimally invasive surgical technique, it is usually recommended in patients with an initial residual bone height (RBH) of between 7 and 9 mm. When the RBH is  $\geq 4$  mm and  $< 6$  mm, sinus-lift and simultaneous implant placement are recommended. In patients with atrophic posterior maxillae (RBH  $< 4$  mm), the standard of care is to perform a lateral sinus-lift with delayed implant placement after graft healing.<sup>18</sup>

To simplify and shorten the duration of rehabilitation of the atrophic maxilla, some authors exceed the recommendations to use OSFE in patients with an RBH of  $< 5$  mm. Nedir et al.<sup>13</sup> treated maxillary sites with an RBH of  $\leq 4$  mm with an overall success rate of 94.6% after 1 year. A literature review reported that the implant survival rate reached 92.7% at sites with an RBH of  $< 5$  mm over 5 years, and no significant difference was evident in relation to the use of grafting material.<sup>3</sup> Furthermore, placement of short implants allows the successful treatment of atrophic sites,<sup>11,19</sup> with predictable implant function for up to 5 years.<sup>20</sup> The tapered shape and reduced pitch of these implants substantially improve their primary stability.<sup>12</sup>

However, the question of whether minimal RBH allows the predictable use of OSFE remains unresolved. Some studies<sup>21,22</sup> report that an RBH of  $< 5$  mm reduces the implant survival rate. Two studies<sup>13,23</sup> describe the performance of implants placed by OSFE in an RBH of  $\leq 4$  mm. The purpose of this study is to further evaluate the efficacy of the OSFE procedure in atrophic maxillae (RBH  $\leq 4$  mm) over a 3-year period. This evaluation should confirm the predictability and lasting performance of the procedure. The study was designed to compare the outcome of short tapered implants randomly placed without (test) or with (control) grafting. The following null

hypothesis was tested: there is no difference in the 3-year radiographic outcome and clinical function of implants placed in an RBH of  $\leq 4$  mm when OSFE is performed without or with grafting. Endo-sinus bone gain (ESBG), crestal bone loss (CBL) and available proximal bone anchorage were measured and compared 1 and 3 years after implant placement. The stability of the bony dome formed by the presence of grafting material above control implants was also analyzed.

## **MATERIALS AND METHODS**

### **Patients**

This study was approved by the ethics committees of the University Hospital of Geneva, Switzerland, and the University of Lausanne, Switzerland, for human research under the protocol reference numbers 06-089 and 245/06, respectively. Informed consent was obtained from all participants. The study was conducted in accordance with the Declaration of Helsinki (2002) and guidelines issued by the ethics committees. Patients were recruited between June 2007 and February 2009 according to the following inclusion criteria:

- Patient requires implant treatment in the posterior maxilla.
- Tooth extraction at the implant sites was performed at least 4 months before surgery.
- RBH between the alveolar bone crest and the sinus floor, measured on panoramic radiograph at each implant site, is  $\leq 4$  mm.
- OSFE is performed with or without grafting material according to the randomization process.
- Straumann® Tapered Effect implants with SLActive® surface, 4.1/4.8 mm in diameter and 8 mm in length (Straumann AG, Basel, Switzerland), are placed.
- Patient agrees to avoid wearing a removable prosthesis at the implant site during the healing period.
- Absence of medical history of acute or chronic sinusitis.
- Absence of active periodontal disease, diabetes and metabolic bone disease.

Initial RBH was measured by orthopantomography. Sinus randomization was assigned at the time of surgery after implant bed preparation.<sup>13</sup>

### **Implant placement and prosthetic rehabilitation**

All treatment procedures were conducted in a private practice setting (Ardentis Clinique Dentaire Vevey, Vevey, Switzerland) as reported previously.<sup>13</sup> Sinuses randomized to the control group were filled with 0.5 cm<sup>3</sup> of anorganic bovine bone (Bio-Oss®; Geistlich Pharma AG, Wolhusen, Switzerland; granulometry: 0.25-1 mm); otherwise, implants were placed without grafting material (test group). After 8 weeks of healing, an impression was taken and the conventional prosthetic steps for single-screwed crown rehabilitation were conducted.

### **Success criteria**

Implants were controlled at 1, 8 (impression time), 10 (prosthesis delivery) and 12 weeks and at 1 and 3 years after implant placement. The success criteria were:

- No pain or any subjective sensation;
- No recurrent peri-implant infection;
- No clinically detectable implant mobility; and
- No continuous radiolucency around the implant.<sup>24</sup>

### **Radiographic measurements**

Standardized peri-apical radiographs were taken immediately after surgery, at 8 weeks and at 1 and 3 years; the 10-week radiograph of the implants with definitive crowns in place was not standardized (Figure 1). Implant placement served as the baseline. Internal calibration was realized on each standardized radiograph by measuring three inter-thread distances (2.4 mm). The peri-apical endo-sinus bone level, peri-apical crestal bone level and proximal bone anchorage along the implants were recorded on the mesial and distal sides of the implant. Graft height above the implant apex - that is, the dome height formed by the graft placement - was

measured in the control group along the implant axis. Figure 2 details the radiographic landmarks.

### **Statistical analysis**

When considering the differences in mean ESBG measured in the test and control groups as the primary outcome, the power of the 1-year study to detect a true difference of at least 1.0 mm, with a standard deviation of 1.3 mm, between the test and control groups was estimated to be 89%.<sup>13</sup>

Descriptive statistics - mean, standard deviation, median and range - were used to present bone level measurements. Data were analysed using mixed linear models that included a random effect (random intercept) for each patient and a fixed effect for the treatment group and year. The p-values took into account the random effects factor. The comparison of success rates between implant groups was tested using Fisher's exact test. The threshold value for statistical significance was set at  $p < 0.05$ .

## **RESULTS**

### **Patients and implants**

Twelve patients (9 women and 3 men, with a mean age of  $57.6 \pm 4.7$  years) were enrolled and 37 sites (32 molars and 5 premolars, 19 sinuses) were treated. All sites presented an RBH of  $\leq 4$  mm (mean:  $2.4 \pm 0.9$  mm; range: 0.9–4.0 mm). Through randomization, 17 implants were placed without grafting (test group; 9 patients, 9 sinuses) and 20 implants were placed with grafting material (control group; 10 patients, 10 sinuses).

### **Clinical observations**

Postoperative observations are described in a previous publication.<sup>13</sup> Mean healing time was  $2.6 \pm 0.9$  months. At this time point, two control implants placed in merged corticals (RBH: 1.4 and 1.2 mm) were clinically mobile and were removed. At 2.7 years, one osseointegrated test implant was removed (RBH: 2.8 mm) because of

peri-implantitis. The patient concerned received periodontal therapy before implant placement. He showed stable periodontal status at the time of implant placement but did not attend periodontal follow-up appointments. The other 34 implants (16 test and 18 control) were successful and the patients reported complete satisfaction. The overall implant success rate was 91.9% after 3 years. It was 94.1% for the test group and 90.0% for the control group ( $p = 0.66$ ).

### **Radiographic evaluation**

Mean bone levels measured from radiographs are summarized in Table 1. All implants gained endo-sinus bone. After 1 year, mean ESBG was  $3.9 \pm 1.0$  mm (test) and  $5.0 \pm 1.3$  mm (control). After 3 years, it reached  $4.1 \pm 1.0$  mm (test) and  $5.1 \pm 1.2$  mm (control). The difference in mean ESBG between the test and control groups was statistically significant at 1 ( $p < 0.001$ ) and 3 years ( $p = 0.001$ ). Mean CBL was limited, without significant difference between the groups. The 3-year mean proximal bone anchorage reached  $6.7 \pm 1.0$  mm (test) and  $8.0 \pm 1.3$  mm (control). The mean ESBG, CBL and proximal bone anchorage did not change significantly between 1 and 3 years ( $p = 0.272$ ,  $0.371$  and  $0.489$ , respectively).

An ESBG  $>4$  mm was observed for 53.1% implant sides when no grafting as used whereas it was observed for 87.8% implant sides when implants were placed with grafting material (Table 2). Four (12.5%) test and 17 (47.2%) control implant sides showed a bone anchorage higher than 8 mm. Twenty-seven implant sides gained crestal bone height (0.5 mm in average). CBL was higher than 2 mm at nine implant sides (Table 2). One test and one control implants, respectively, showed a mesial CBL of 3.1 mm with a mesial height of bone anchorage reaching 5.3 and 5.4 mm respectively. This extreme CBL had no influence on their 3-year stability.

The dome formed by grafting material above the implants in the control group showed a mean height of  $1.6 \pm 0.9$  mm immediately after surgery. At 1 year, 13



implants in the control group were completely embedded in the peri-implant bony material. The mean bony material height above the apex of these 13 implants was  $1.3 \pm 0.7$  mm. At 3 years, 11 implants were embedded. The mean height above the apex of these implants was  $1.1 \pm 0.7$  mm. The differences between dome height measurements after surgery and 1 year, and after surgery and at 3 years, were not significant ( $p = 0.182$  and  $0.116$ , respectively). Only two implants in the test group were completely embedded at 1 and 3 years.

## **DISCUSSION**

Although the RBH was  $< 4$  mm at all implant sites, the patients included in this study were treated by OSFE and simultaneous placement of short tapered implants. At 3 years, all sites but three were successfully rehabilitated. The OSFE technique proved predictable, with a success rate of 91.9% after 3 years. This was slightly higher than the value of 85.7% presented by Rosen et al.<sup>21</sup> for implants placed by OSFE in a non-augmented RBH of  $\leq 4$  mm, and almost equivalent to the 92.7% reported by Del Fabbro et al.<sup>3</sup> for 331 implants placed in an RBH of  $< 5$  mm.

According to the 1996 consensus conference on sinus lifting,<sup>18</sup> the recommended treatment of the atrophic posterior maxilla is sinus floor augmentation through the lateral approach with bone grafting. A staged approach is generally suggested when RBH is judged insufficient to guarantee the primary stability of implants. The survival rate of implants placed using the sinus-lift technique and delayed implant placement ranges from 72.7% to 100% (mean: 93.7%).<sup>25</sup> Unfortunately, the graft failure rate alone (cases of re-graft surgery, aborted sinus membrane elevation or sinus elevation without implants being placed) was not included.<sup>18</sup> It is estimated to be 1.9% (range: 0-17.9%).<sup>1</sup> In this study, the survival rate of implants placed with OSFE was comparable to that reported for implants placed using sinus-lift.<sup>25</sup>

Three failures (two early and one late) were recorded in this study. The early failures related to the placement of implants in fused corticals (monocortical bone), but not to the presence or lack of grafting material.<sup>13</sup> The late failure occurred in a patient with a history of periodontitis. A history of periodontitis can jeopardize the longevity and survival rate of implant treatment;<sup>26</sup> therefore, the late failure reported here could be attributed to the periodontal status of the patient and not the OSFE procedure.

This study tested the feasibility and success of the OSFE procedure in patients with extremely limited RBH (mean:  $2.4 \pm 0.9$  mm; range: 0.9-4.0 mm). A meta-regression analysis of 12 studies that used the lateral procedure (406 patients, 1644 implants) identified a positive association between initial RBH and implant survival rates.<sup>27</sup> The implant survival rate showed a positive trend when initial RBH rose from 1 to 5 mm and became stable at a high survival rate when the RBH was  $> 5$  mm. RBH may be crucial for implant survival using the sinus-lift technique. However, an analysis of nine studies that used the OSFE technique (383 patients, 618 implants) showed no relationship between initial RBH and implant survival rate.<sup>27</sup> This might have been due to a lack of data from patients with an RBH of  $< 4$  mm. Most studies selected patients with a maxillary RBH of  $> 4$  mm and the few studies in patients with an RBH of  $< 4$  mm report a survival rate of close to 100%.<sup>27</sup> Recently, Gonzalez et al.<sup>28</sup> reported that the crestal approach for maxillary sinus floor elevation is a viable technique for use in patients with minimal RBH ( $\leq 4$  mm). Therefore, RBH can no longer be considered the single deciding factor for the selection of either sinus-lift or OSFE. Other important factors that should contribute to the decision-making process include the patient preference, the experience of the practitioner, morbidity and the invasiveness and complexity of the procedure.

The Schneiderian membrane can support elevation of 4-8 mm without perforation;<sup>29</sup> therefore, most 8-mm implants placed with grafting were embedded into the bony dome. Also 8-mm implants placed without grafting could be embedded in bone. Therefore, the 8-mm implants could be particularly advantageous for the rehabilitation of atrophic posterior maxillae. The need for grafting was avoided by gaining at least 4 mm of bone. Their osseointegrated surface was sufficient to function successfully over 3 years of functional loading.

The use of graft material may not improve primary stability of the implant. The residual original bone seems to be the key factor for primary implant stability. When primary stability is a concern, increasing bone compression through the use of tapered implants with a reduced pitch - and, therefore, more threads - may be beneficial.<sup>30</sup> In this study, it was surprising that the osseointegration of implants into atrophic soft bone allowed functional loading of the definitive prostheses after a healing time of just 10 weeks. In such a limited healing time, the contribution of the endo-sinus newly formed bone to the support of mechanical loading of the occlusion is questionable. Once osseointegration is achieved and implants are loaded, there should be an effective load transfer from implant to bone. The application of load results in high stress in the crestal bone immediately around the neck of loaded implants.<sup>31,32</sup> Consequently, the first 3-5 threads are involved in stress absorption. For long-term mechanical and clinical stability, the presence of an RBH of 1-2 mm and at least 3-4 mm of regenerated bone could provide sufficient bony anchorage to permit stress distribution. A high amount of crestal bone (>3 mm) was lost at one side of two implants, but the available bone anchorage had still reached 5.3 mm; the augmented bone rendered the implants stable over time. The OSFE technique without grafting material increases the bone height around 8-mm implants by 4.1 mm on average. In

the absence of grafting, ESG was limited to the height of the implant apex, around which the Schneiderian membrane might collapse.<sup>33</sup> In this study, the mean bone anchorage height along 8-mm implants in the test group reached  $6.7 \pm 1.0$  mm. This was sufficient to support functional loading over 3 years. To increase bone anchorage, the sinus membrane must be maintained in an elevated position.<sup>34</sup> The presence of grafting material, as well as adjacent implants, maintains the membrane at the distance of the implant body;<sup>13</sup> as a result, proximal bone anchorage reached  $8.0 \pm 1.3$  mm after 3 years.

Bone levels measured around implants at 1 year remained stable at 3 years. The bone height gained without grafting should remain stable for over 5 years<sup>20</sup> and has been observed to be unchanged at 16 years.<sup>15</sup> When implants were placed with grafting, a slight decrease in dome height above the implant apex was observed at a 3-year follow-up. The remodelling of graft apical to implants was observed by Bragger et al.<sup>35</sup> after 1 year (19 patients, 25 implants) and by Si et al.<sup>16</sup> within 3 years (21 patients, 21 implants). These authors reported a significant height reduction resulting from the use of autogenous bone chips mixed with anorganic bovine bone material. Shrinkage of the 2:1 autogenous bone:xenograft mixture could approach the implant apex or fall slightly below it but can stabilize over time; however, this may take up to 10 years.<sup>36</sup> The resorption rate of autogenous bone is high, particularly when cancellous bone is used.<sup>37</sup> However, its presence accelerates early bone-implant contact formation adjacent to the implant surface.<sup>38</sup> Anorganic bovine bone material appears to undergo slow or even no resorption for up to 10<sup>39</sup> or 11<sup>40</sup> years. Although the results obtained in the present study by using two-dimensional radiography were pertinent, a more accurate and reliable evaluation of dome remodelling might be provided by cone beam-computerized tomography (CB-CT).<sup>41</sup>

In the extreme conditions presented in this study, such as very low maxillary RBH and the use of short implants, both *de novo* bone and composite regenerated mineralized tissue have shown their ability to support loading stress during a 3-year period. However, long-term studies are needed to investigate the following in these extreme conditions:

- the efficiency of the OSFE procedure with and without grafting;
- the effect of a composite bony material above the implant apex on the implant success and survival rates; and
- the relationship between RBH and the survival rate of implants placed with OSFE.

## **CONCLUSION**

This study showed that short tapered implants with a reduced thread pitch can be placed with good primary stability in atrophic maxillae using OSFE. After 3 years, 91.9% of implants placed with or without grafting demonstrated successful integration and functional loading. The regenerative properties of the bone within the sinus led to marked endo-sinus bone formation, even without grafting material. Grafting is not necessary to attain an ESBG of 4.1 mm. However, greater ESBG is achieved when grafting material is inserted. Crestal and endo-sinus bone levels observed after 1 year are preserved after 3 years. Most complications occurred early and they rarely occurred after implant osseointegration. For patients presenting risk factors such as a history of periodontitis, strict follow-up is recommended. The atrophic posterior maxilla can be rehabilitated using OSFE and the simultaneous placement of 8-mm implants. This procedure offers patients a simpler and less invasive implant treatment for atrophic maxillae.

**ACKNOWLEDGMENTS**

The authors are grateful to Professor Thomas Perneger (Clinical Research Center, University Hospitals of Geneva, Switzerland) for statistical assistance. The ITI Foundation is acknowledged for its financial support during the first year of the study (grant no 428/2005). The authors declare that they have no conflict of interests.

## REFERENCES

1. Pjetursson BE, Tan WC, Zwahlen M, Lang NP. A systematic review of the success of sinus floor elevation and survival of implants inserted in combination with sinus floor elevation. Part I: Lateral approach. *J Clin Periodontol* 2008; 35(Suppl 8):216-240.
2. Summers RB. A new concept in maxillary implant surgery: the osteotome technique. *Compend Contin Educ Dent* 1994; 15:152-160.
3. Del Fabbro M, Corbella S, Weinstein T, Ceresoli V, Taschieri S. Implant survival rates after osteotome-mediated maxillary sinus augmentation: A systematic review. *Clin Implant Dent Rel Res* 2012; 14(Suppl 1):e159-e168.
4. Tan WC, Lang NP, Zwahlen M, Pjetursson BE. A systematic review of the success of sinus floor elevation and survival of implants inserted in combination with sinus floor elevation. Part II: Transalveolar technique. *J Clin Periodontol* 2008; 35(Suppl 8):241-254.
5. Lundgren S, Andersson S, Gualini F, Sennerby L. Bone reformation with sinus membrane elevation: A new surgical technique for maxillary sinus floor augmentation. *Clin Implant Dent Relat Res* 2004; 6:165-173.
6. Chen TW, Chang HS, Leung KW, Lai YL, Kao SY. Implant placement immediately after the lateral approach of the trap door window procedure to create a maxillary sinus lift without bone grafting: a 2-year retrospective evaluation of 47 implants in 33 patients. *Int J Oral Maxillofac Surg* 2007; 65: 2324-2328.
7. Hatano N, Sennerby, L, Lundgren S. Maxillary sinus augmentation using sinus membrane elevation and peripheral venous blood for implant-supported rehabilitation of the atrophic posterior maxilla: case series. *Clin Implant Dent Rel Res* 2007; 9:150-155.

8. Lin IC, Gonzalez AM, Chang HJ, Kao SY, Chen TW. A 5-year follow-up of 80 implants in 44 patients placed immediately after the lateral trap-door window procedure to accomplish maxillary sinus elevation without bone grafting *Int J Oral Maxillofac Implants* 2011; 26:1079-1086.
9. Wallace SS, Froum SJ. Effect of maxillary sinus augmentation on the survival of endosseous dental implants. A systematic review. *Ann Periodontol* 2003; 8:328-343.
10. Li TF. Sinus floor elevation: a revised osteotome technique and its biological concept. *Compend Contin Educ Dent* 2005; 26:619-627.
11. Nedir R, Bischof M, Vazquez L, Szmukler-Moncler S, Bernard JP. Osteotome sinus floor elevation without grafting material: a 1-year prospective pilot study with ITI implants. *Clin Oral Implants Res* 2006; 17:679-686.
12. Nedir R, Nurdin N, Szmukler-Moncler S, Bischof M. Placement of tapered implants using an osteotome sinus floor elevation technique without grafting material: 1-year results. *Int J Oral Maxillofac Implants* 2009; 24:727-733.
13. Nedir R, Nurdin N, Khoury P, et al. Osteotome sinus floor elevation with and without grafting material in the severely atrophic maxilla. A 1-year prospective randomized controlled study. *Clin Oral Implants Res* 2013; 24:1257-1264.
14. Lai HC, Zhuang LF, Lv XF, Zhang ZY, Zhang YX, Zhang ZY. Osteotome sinus floor elevation with or without grafting: a preliminary clinical trial. *Clin Oral Implants Res* 2010; 21:520-526.
15. Bruschi GB, Crespi R, Capparè P, Gherlone E. Transcrestal sinus floor elevation: A retrospective study of 46 patients up to 16 year. *Clin Implant Dent Rel Res* 2012; 14,759-767.



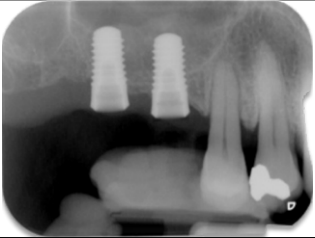
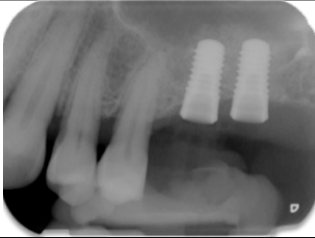
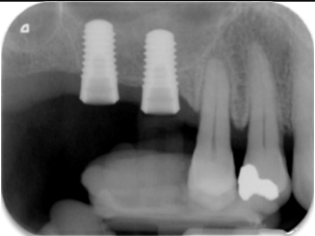
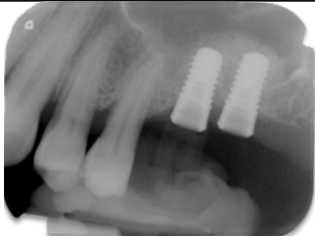
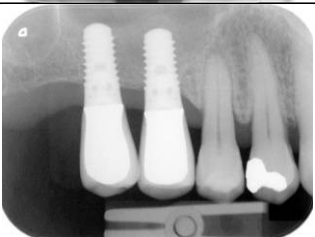
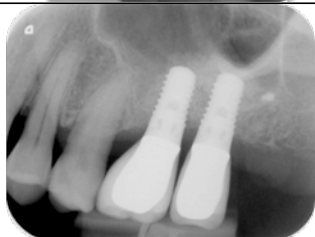
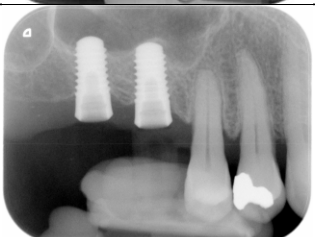





16. Si MS, Zhuang LF, Gu YX, Mo JJ, Qiao SC, Lai HC. Osteotome sinus floor elevation with or without grafting: a 3-year randomized controlled clinical trial. *J Clin Periodontol* 2013; 40:396-403.
17. Palma VC, Magro-Filho O, de Oliveria JA, Lundgren S, Salata LA, Sennerby L. Bone reformation and implant integration following maxillary sinus membrane elevation: an experimental study in primates. *Clin Implant Dent Relat Res* 2006; 8:11-24.
18. Jensen OT, Shulman LB, Block MS, Iacono VJ. Report of the sinus consensus conference of 1996. *Int J Oral Maxillofac Implants* 1998; 13(Suppl):11-32.
19. Nedir R, Bischof M, Vazquez L, Nurdin N, Szmukler-Moncler S, Bernard JP. Osteotome sinus floor elevation technique without grafting material: 3-year results of a prospective pilot study. *Clin Oral Implants Res* 2009; 20:701-707.
20. Nedir R, Nurdin N, Vazquez L, Szmukler-Moncler S, Bischof M, Bernard JP. Osteotome sinus floor elevation technique without grafting material: A five-year prospective study. *J Clin Periodontol* 2010; 37:1023-1028.
21. Rosen PS, Summers R, Mellado JR, Salkin LM, Shanaman RH, Marks MH. The bone-added osteotome sinus floor elevation technique: multicenter retrospective report of consecutively treated patients. *Int J Oral Maxillofac Implants* 1999; 14:853-858.
22. Toffler M. Osteotome-mediated sinus floor elevation: A clinical report. *Int J Oral Maxillofac Implants* 2004; 19:266-273.
23. Gonzalez S, Tuan MC, Ahn KM, Nowzari H. Crestal approach for maxillary sinus augmentation in patients with  $\leq 4$  mm of residual alveolar bone. *Clin Implant Dent Relat Res* 2013. doi: 10.1111/cid.12067.

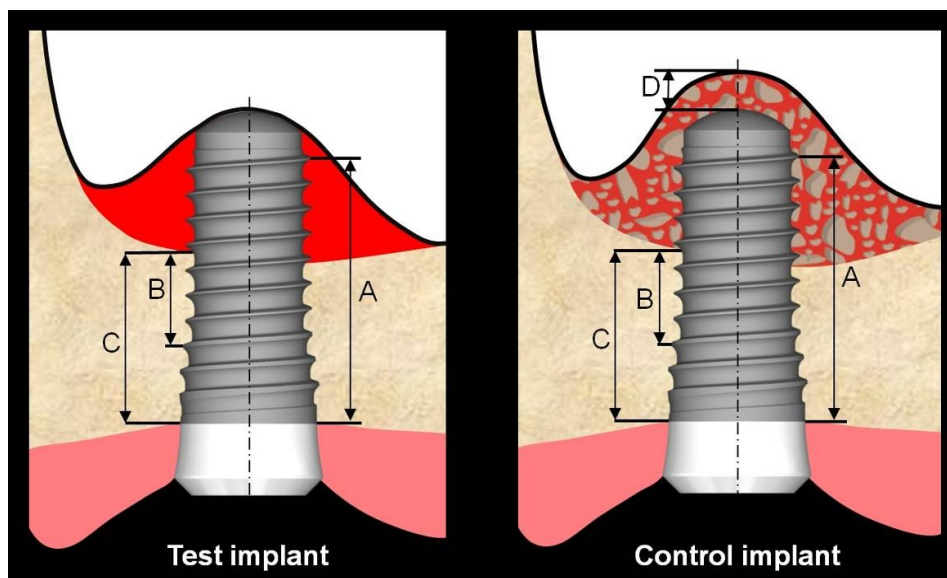
24. Buser D, Mericske-Stern R, Bernard JP, et al. Long-term evaluation of non-submerged ITI implants. Part 1: 8-year life table analysis of a prospective multi-center study with 2359 implants. *Clin Oral Implants Res* 1997; 8:161-172.
25. Chiapasco M, Casentini P, Zaniboni M. Bone augmentation procedures in implant dentistry. *Int J Oral Maxillofac Implants* 2009; 24(Suppl):237-259.
26. Levin L, Ofec R, Grossmann Y, Anner R. Periodontal disease as a risk for dental implant failure over time: A long-term historical cohort study. *J Clin Periodontol* 2011; 38:732-737.
27. Chao YL, Chen HH, Mei CC, Tu YK, Lu HK. Meta-regression analysis of the initial bone height for predicting implant survival rates of two sinus elevation procedures. *J Clin Periodontol* 2010; 37:456-465.
28. Gonzalez S, Tuan MC, Ahn KM, Nowzari H. Crestal approach for maxillary sinus augmentation in patients with  $\leq 4$  mm of residual alveolar bone. *Clin Implant Dent Relat Res* 2013; DOI 10.1111/cid.12067.
29. Reiser GM, Rabinovitz Z, Bruno J, Damoulis PD, Griffin T. Evaluation of maxillary sinus membrane response following elevation with the crestal osteotome technique in human cadavers. *Int J Oral Maxillofac Implants* 2001; 16:833-840.
30. O'Sullivan D, Sennerby L, Meredith N. Influence of implant taper on the primary and secondary stability of osseointegrated titanium implants. *Clin Oral Implants Res* 2004; 15:474-480.
31. Abu-Hammad O, Khraisat A, Dar-Odeh N, Jagger DC, Hammerle CHF. The Staggered Installation of Dental Implants and Its Effect on Bone Stresses. *Clin Implant Dent Rel Res* 2007; 9:121-127.

32. Pierrisnard L, Renouard F, Renault P, Barquins M. Influence of Implant Length and Bicortical Anchorage on Implant Stress Distribution. *Clin Implant Dent Rel Res* 2003; 5:254-262.
33. Sul SH, Choi BH, Li J, Jeong SM, Xuan F. Effects of sinus membrane elevation on bone formation around implants placed in the maxillary sinus cavity: an experimental study. *Oral Surg Oral Med Oral Pathol Oral Radiol Endod* 2008; 105:684-687.
34. Scala A, Botticelli D, Faeda RS, Rangel IG Jr, de Oliveira JA, Lang NP. Lack of influence of the Schneiderian membrane in forming new bone apical to implants simultaneously installed with sinus floor elevation: an experimental study in monkeys. *Clin Oral Implants Res* 2012; 23:175-181.
35. Brägger U, Gerber C, Joss A, et al. Patterns of tissue remodeling after placement of ITIs dental implants using an osteotome technique: a longitudinal radiographic case cohort study. *Clin Oral Implants Res* 2004; 15:158-166.
36. Hatano N, Shimizu Y, Ooya K. A clinical long-term radiographic evaluation of graft height changes after maxillary sinus floor augmentation with a 2: 1 autogenous bone/xenograft mixture and simultaneous placement of dental implants. *Clin Oral Implants Res* 2004; 15:339-345.
37. Haas R, Donath K, Födinger M, Watzek G. Bovine hydroxyapatite for maxillary sinus augmentation. Comparative histomorphometric findings in sheep. *Clin Oral Implants Res* 1998; 9:107-116.
38. Jensen T, Schou S, Gundersen HJG, Forman JL, Terheyden H, Holmstrup P. Bone-to-implant contact after maxillary sinus floor augmentation with Bio-Oss and autogenous bone in different ratios in minipigs. *Clin Oral Implants Res* 2013; 24:635-644.

39. Mardinger O, Chaushu G, Sigalov S, Herzberg R, Shlomi B, Schwartz-Arad D. Factors affecting changes in sinus graft height between and above the placed implants. *Oral Surg Oral Med Oral Pathol Oral Radiol Endod* 2011; 111(1):e6-e11.
40. Mordenfeld A, Hallman M, Johansson CB, Albrektsson T. Histological and histomorphometrical analyses of biopsies harvested 11 years after maxillary sinus floor augmentation with deproteinized bovine and autogenous bone. *Clin Oral Implants Res* 2010; 21:961-970.
41. He LL, Chang X, Liu Y. Sinus floor elevation using osteotome technique without grafting materials: a 2-year retrospective study. *Clin Oral Implants Res* 2013; 24 (Suppl. A100):63-67.

	Test (no grafting)	Control (grafting)
Preoperative		
Postoperative		
8 weeks		
10 weeks		
1 year (crown deposit)		
3 years (crown deposit)		

**Figure 1** Radiographic evolution of sinus floor level over 3 years in Patient #3.



**Figure 2** Radiographic measurements of crestal bone loss, endo-sinus bone gain

and proximal bone anchorage.

Distance **A**, parallel to the implant axis and between the most coronal bone-implant contact and the most apical implant thread, was measured on both sides of each implant and averaged. A decrease in this mean value on consecutive radiographs, taken immediately after implant surgery and at 1 and 3 years, was indicative of crestal bone loss.

Distance **B**, between a reference coronal implant thread and the most apical implant-bone contact, was measured on both sides of each implant and averaged. An increase in this mean value on consecutive radiographs, taken immediately after implant surgery and at 1 and 3 years, was indicative of endo-sinus bone gain.

Distance **C**, between the most coronal bone-implant contact and the most apical bone-implant contact, was measured on both sides of each implant and averaged; graft height **D** above the control implant apex was also measured along the implant axis. **C** and **C + D**, respectively, expressed the available proximal bone anchorage for the test and control implants, respectively.

Implant group		1 year			3 years		
		Test (no grafting) 34 implant sides	Control (grafting) 36 implant sides	<i>p</i> *	Test (no grafting) 32 implant sides	Control (grafting) 36 implant sides	<i>p</i> *
<b>Endo-sinus bone gain</b>	Mean	3.9 mm	5.0 mm	<0.001	4.1 mm	5.1 mm	0.001
	standard deviation	1.0 mm	1.3 mm		1.0 mm	1.2 mm	
	median	4.1 mm	5.1 mm		4.4 mm	5.3 mm	
	range	1.8 - 6.2 mm	2.9 - 6.7 mm		1.5 - 7.0 mm	2.0 - 7.0 mm	
<b>Crestal bone loss</b>	Mean	0.6 mm	0.4 mm	0.53	0.6 mm	0.5 mm	0.99
	standard deviation	0.8 mm	0.7 mm		1.1 mm	1.0 mm	
	median	0.5 mm	0.3 mm		0.5 mm	0.2 mm	
	range	0 - 2.4 mm	0 - 2.1 mm		0.0 - 3.1 mm	0.0 - 3.1 mm	
<b>Bone anchorage</b>	Mean	6.5 mm	8.2 mm	<0.001	6.7 mm	8.0 mm	<0.001
	standard deviation	1.0 mm	1.5 mm		1.0 mm	1.3 mm	
	median	6.4 mm	8.5 mm		6.7 mm	8.0 mm	
	range	4.6 - 8.2 mm	5.4 - 10.3 mm		4.7 - 8.9 mm	5.4 - 10.5 mm	

**Table 1** Radiographic bone levels at 1 and 3 years.

\*Statistical significance of mean bone level difference between test and control groups.

		<b>Test (no grafting)</b>	<b>Control (grafting)</b>
		<b>Number of implant sides (%)</b>	<b>Number of implant sides (%)</b>
<b>Endo-sinus bone gain</b>	<b>0-2 mm</b>	2 (6.2%)	0 (0%)
	<b>2-4 mm</b>	13 (40.7%)	8 (22.2%)
	<b>4-6 mm</b>	16 (50.0%)	18 (50.0%)
	<b>&gt;6 mm</b>	1 (3.1%)	10 (27.8%)
<b>Crestal bone level</b>	<b>loss &gt;3 mm</b>	1 (3.1%)	1 (2.8%)
	<b>loss 2-3 mm</b>	3 (9.4%)	4 (11.1%)
	<b>loss 1-2 mm</b>	8 (25.0%)	6 (16.7%)
	<b>loss 0-1 mm</b>	9 (28.1%)	9 (25.0%)
	<b>gain</b>	11 (34.4%)	16 (44.4%)
<b>Bone anchorage</b>	<b>4 - 8 mm</b>	28 (87.5%)	19 (52.8%)
	<b>&gt; 8 mm</b>	4 (12.5%)	17 (47.2%)

**Table 2** Frequency analysis of the 3-year endo-sinus bone gain, crestal bone loss and bone anchorage measured at each implant side of test and control implants.